

## Contrast Enhancement of Mammograms for Rapid Detection of Microcalcification Clusters

Hajar Moradmand<sup>1</sup>, Saeed Setayeshi<sup>1</sup>, Alireza Karimian<sup>2\*</sup>, Mehri Sirous<sup>3</sup>

### Abstract

#### Introduction

Breast cancer is one of the most common types of cancer among women. Early detection of breast cancer is the key to reducing the associated mortality rate. The presence of microcalcifications clusters (MCCs) is one of the earliest signs of breast cancer. Due to poor imaging contrast of mammograms and noise contamination, radiologists may overlook some diagnostic signs, specially the presence of MCCs. In order to improve cancer detection, image enhancement methods are often used to aid radiologists. In this paper, a new enhancement method was presented for the accurate and early detection of MCCs in mammograms.

#### Materials and Methods

The proposed system consisted of four main steps including: 1) image scaling; 2) breast region segmentation; 3) noise cancellation using a filter, which is sensitive to MCCs; and 4) contrast enhancement of mammograms using Contrast-Limited Adaptive Histogram Equalization (CLAHE) and wavelet transform. To evaluate this method, 120 clinical mammograms were used.

#### Results

To evaluate the performance of the image enhancement algorithm, contrast improvement index (CII) was used. The proposed enhancement method in this research achieved the highest CII in comparison with other methods applied in this study. The Validity of the results was confirmed by an expert radiologist through visual inspection.

#### Conclusion

Detection of MCCs significantly improved in contrast-enhanced mammograms. The proposed method could be helpful for radiologists to easily detect MCCs; it could also decrease the number of biopsies and reduce the frequency of clinical misdiagnosis. Moreover, it could be useful prior to segmentation or classification stages.

**Keywords:** Breast Cancer, Image Enhancement, Wavelet Transform.

---

1- Department of Biomedical-Radiation Engineering, Amirkabir University of Technology, Tehran, Iran

2- Department of Biomedical Engineering, Faculty of Engineering, University of Isfahan, Isfahan, Iran

\*Corresponding author: Tel: +98 313793-4059; E-mail: [karimian@eng.ui.ac.ir](mailto:karimian@eng.ui.ac.ir)

3- Department of Radiology, Isfahan University of Medical Sciences, Isfahan, Iran

### 1. Introduction

Breast cancer is one of the major causes of mortality among women. In Iran, patients with breast cancer are at least one decade younger than their counterparts in developed countries; i.e., age of breast cancer development has reduced from 40 to 30 years [1]. This is a serious problem in our country and further research is required in this area. Since causes of breast cancer remained unknown, there is no assured way to prevent it; therefore, the best way to fight this disease is early diagnosis in early stages of the disease.

The appearance of microcalcifications (MCs) in mammograms is one of the first signs in 30-50% of breast cancers [2]. MCs are tiny specks of calcium in the breast, and are produced due to various reasons including breast cancer. MCs can be often seen in malignant tissues as cluster patterns. Microcalcification clusters (MCCs) in 60-80% of breast cancers have been observed after histological examination [3]. Considering the significant correlation between the presence of MCCs and breast cancer, early detection of these signs on mammograms can help control breast cancer.

Generally, MCs have small sizes (range of about 0.1 mm to 0.7 mm) and low contrast; therefore, they may be overlooked or misinterpreted by radiologists. In fact, eye-based mammography screening is a tedious task, and about 10-30% of these signs is overlooked by physicians [4]. Physicians are responsible for the final confirmation of a disease, thus, due to misdiagnosis, many patients may undergo unnecessary biopsies, which result in the patient's pain and unnecessary costs. Moreover, lack of early diagnosis can result in the patient's death, and under the best circumstances, it may lead to the complete removal of breast tissue.

Considering the difficulties and the importance of detecting MCCs in breast cancer diagnosis, the need to use automatic methods is strongly felt in order to prevent the development of cancer cells. Recently, computer-aided diagnosis (CAD) systems have improved the detection of abnormalities in mammograms, and are used as a "second opinion". Depending

on the skills of a radiologist, the reader's sensitivity can be increased by approximately 10-15% with the assistance of CAD systems [5].

A CAD system generally consists of four stages of preprocessing, image segmentation, feature extraction, and classification of features [5]. Preprocessing in the CAD system significantly affects other stages. Effective preprocessing decreases the error rate in the next steps, and thus, the total number of errors in the system is reduced. With proper preprocessing, the minimum number can be selected as primary suspected MCCs; this would accelerate the classification stage.

MCs appear in very small sizes and various patterns on mammography images. Therefore, it is very difficult to identify them if they are not formed as concentrated clusters. Also, factors such as the large size and the low contrast of mammograms, as well as the small size, various patterns, and limited number of MCCs, can increase the processing time in CAD systems. To overcome the mentioned problems, image noise must be removed and the contrast between the background region and region of interest (ROI) must be improved. All these operations are performed in the preprocessing stage.

Many algorithms have been proposed to improve the quality of mammograms including histogram modification, median filters, Gaussian filters, morphological filters [6], and fractal models [7]. Recently, researchers have paid particular attention to multi-scale techniques in order to improve the image contrast, and wavelet-based methods are among the highly efficient methods [8].

Although some of these approaches improve the visibility of MCCs, the layout and shape of these calcium deposits may be distorted in images, which may lead to misdiagnosis. Some other methods may increase the noise or destruction to anatomical structures of image in the image. The size and shape of diagnostic indicators significantly change in mammograms and conventional methods are weak in improving various features of mammograms. Therefore, adaptive contrast

enhancement algorithms, in which the focus is on the local content of image, may be helpful [9].

Each of these methods has its own advantages and disadvantages for improving mammogram quality. The aim of this study was to present a new method for improving image contrast in order to detect MCCs earlier and more accurately. This method can also be used in the later stages of CAD system such as segmentation and classification of benign and malignant patterns [10].

The proposed method in this study included four stages. Firstly, the images were scaled since the real size of mammograms was too large. Secondly, the breast tissue was segmented from the image background. Thirdly, noise was removed using a sensitive filter to the shape and size of MCCs (an adaptive median filter was used for this purpose). Finally, the combined method of Contrast-Limited Adaptive Histogram Equalization (CLAHE) and wavelet transform was used for contrast enhancement. We selected the algorithms based on previous studies and tried to eliminate the associated disadvantages to identify features such as the presence of MCCs [11-13].

## 2. Materials and Methods

### 2.1 Data bank

All mammograms in this study were obtained from patients, referring to a radiology center in Isfahan, Iran, in years 2009 - 2011. The data included 120 mammograms containing one or more MCCs. The mean size of images was 4000×6000, with a sample rate of 50 mm and resolution of 8 bits per pixel. These images were converted to digital images using a laser digitizing system.

The large size of these images made the processing, storing, and sending processes very time-consuming and difficult. By using a

method called image scaling [14], the size of images was reduced without losing any significant features of mammograms [15, 16]; image scaling was performed as the first step in the process.

### 2.2 Breast region extraction

Breast tissue occupies only a part of the image and the rest of the image is all black, containing no information. In a mammogram, the types of noise include high-intensity labels, low-intensity labels, and tape artifacts. In order to increase the processing speed and reduce the effects of artifacts, we tried to extract the breast region with a mask template. Consequently, subsequent processing was performed only on breast tissue.

The mask template was a binary matrix with a size equal to that of the original image. Viscosity and density of breast tissue and fat were not similar among different individuals. Therefore, applying the conventional threshold could not provide the desired mask template to properly separate all breast tissue. To overcome this problem, first, a series of morphological operations including erosion and dilation were performed to smooth the mammogram; then, a global threshold was defined.

Intensities less than the defined threshold were set to 0 (black) and higher intensities were set to 1 (white); thus, the images were converted to binary images. However, the visible noises on the mammograms, as mentioned above, still remained outside the zone. To select only the breast region for further processing, morphological operations were used to remove areas smaller than 1000 pixels.

Among the remaining regions, the largest area was selected as a border area between the breast and the black part of the image. An example of an applied mask on the image is shown in Figure 1.




Figure 1. An example of the applied mask on the extracted breast tissue

### 2.3 Noise cancellation

Digital mammograms often contain a substantial amount of impulse noise, which is observed as bright or dark spots (salt or pepper noise) on the image.

So far, various filters have been proposed to reduce this type of noise. The first category of these filters has a good performance in reducing image noise, but it typically destroys image details and makes the image blurry. The second category of these filters preserves image details, though noise reduction is low. The third category removes noise while preserving image edges and details.

Median filter is included in the third category of these filters. This non-linear filter is a powerful and useful tool for improving the quality of mammograms, given its ability to remove impulse noise without blurring the edges [17]. The median filter uses a  $m \times n$  neighborhood and arranges the whole neighborhood in an ascending order. Then, it selects the median of the sorted numbers and substitutes it for the central pixel.

If the image details are not sufficient or the gray levels of pixels are very different from each other, the image is considered blurred despite the use of the median filter. In other words, a simple median filter cannot make a distinction between noise and fine details of the image, and it should be removed.

In this research, adaptive median filter, as a more suitable filter compared to a simple median filter, was used for noise cancellation.

### 2.4 Adaptive median filter

An adaptive median filter implements a spatial operation to determine which pixels of the image are affected by impulse noise. By comparing each pixel in the image with the neighborhood, the pixel is classified as noise; the window size of the neighborhood changes during the operation. Suppose that the image noise is denoted by  $y$  and  $S_{i,j}^w$  is a window with  $w \times w$  size, located in the center of  $(i, j)$ , which:

$$S_{i,j}^w = \{(k; l) : |k - i| \leq w \text{ and } |l - j| \leq w\} \quad (1)$$

Minimum, maximum, and median gray levels in the “ $w$ ” window are calculated, which have the following notations:  $S_{i,j}^{\min,w}$ : minimum gray level in the  $w$ ,  $S_{i,j}^{\max,w}$ : maximum gray level in the  $w$ ,  $S_{i,j}^{\text{med},w}$ : median gray level in the  $w$ ,  $Y_{i,j}$ : gray level at the  $(i, j)$  point of image, and  $w_{\max}$ : the maximum window size of the median filter.

The window size is set in a way that  $S_{i,j}^{\text{med},w}$  is not an impulse noise. If  $Y_{i,j}$  is the impulse noise, it is replaced with  $S_{i,j}^{\text{med},w}$ , otherwise, the output remains unchanged ( $Y_{i,j}$ ) and is not considered an impulse noise [18]. Block diagram of the proposed algorithm for the adaptive median filter is shown in Figure 2.

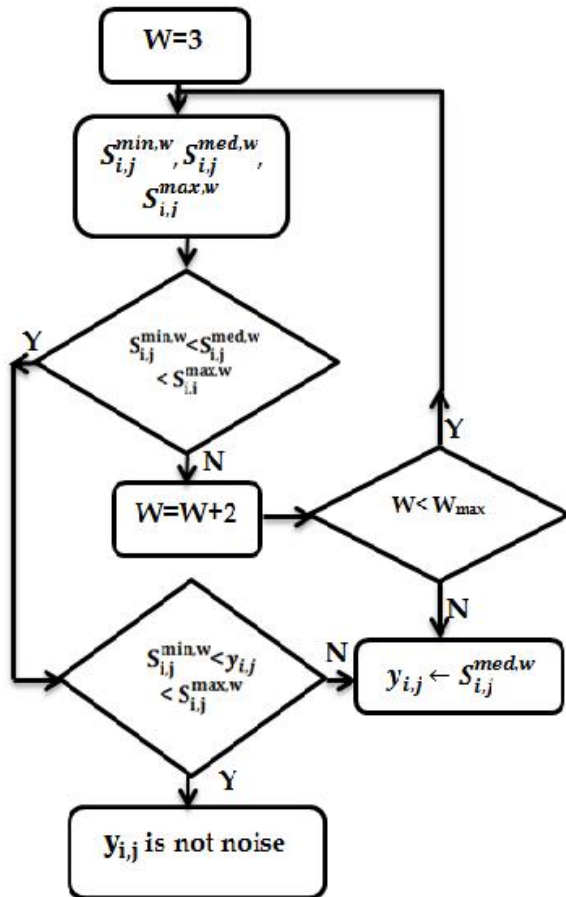


Figure 2. Block diagram of the proposed algorithm of adaptive median filter

**2.5 Contrast enhancement**

In this study, a combination of methods (CLAHE and the wavelet transform) was used to enhance image quality. In the following section, the performances of these methods are

described. For more information, readers can refer to the reference section [19-21].

**2.6.(CLAHE)**

Mammogram histogram is considered as a distribution probability, based on the information theory. A mammogram with a uniform histogram can provide more information. Maximum entropy can be achieved by histogram equalization, although normal tissues and noise will be amplified.

CLAHE can be utilized in a small area of the image (called tiles) rather than the entire image. The contrast of each of these areas is enhanced so that the output corresponds to a specific histogram. Then, the histogram tiles are matched together and form the final image; this could prevent any probable noise amplification in the image [19].

CLAHE is an improved version of Adaptive Histogram Equalization (AHE). CLAHE algorithm partitions the images into contextual regions and applies the histogram equalization for each region; this uniform the distribution of gray values and thus makes hidden features of the image more visible. The contrast, especially in homogeneous areas, can be limited in order to avoid amplifying any noise that might be present in the image. An example of the performance of histogram equalization is shown in Figure 3.

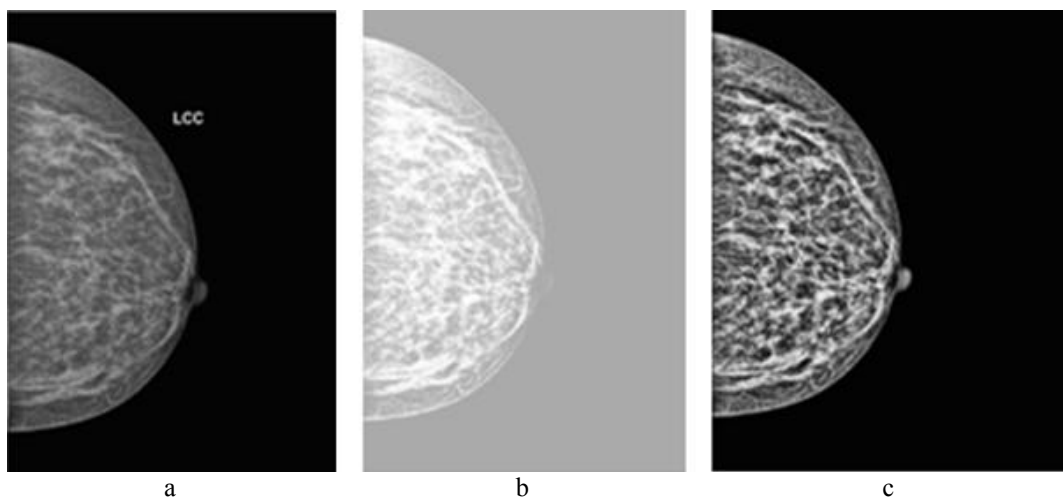


Figure 3. An example of the performance of CLAHE on a mammogram, a) original mammogram, b) enhanced mammogram after applying histogram equalizations, c) enhanced mammogram after applying CLAHE

**2.7 Wavelet transform**

A wavelet transforms a signal into a set of basic functions, which vary in terms of scale factor (s) and position (b), and are derived from the mother wavelet  $\psi(t)$ . Wavelet transform of the signal  $f(t)$  is defined as follows:

$$Wsf(b) = \frac{1}{\sqrt{s}} \int_{-\infty}^{\infty} f(t) \psi\left(\frac{t-b}{s}\right) dt \quad (2)$$

The two-dimensional wavelet transform is applied in image processing. Two-dimensional wavelet transform is obtained by multiplication of the scale ( $\psi$ ) and the wavelet function ( $\phi$ ). A two-dimensional wavelet decomposes an image into one image with approximation coefficient and detail coefficients in three orientations (horizontal, vertical, and diagonal). An approximate coefficient contains large-scale components, though detail coefficients contain small-scaled ones; in frequency-domain analysis, detail coefficients are high-frequency coefficients.

MCCs frequently appear on mammograms as fine bright grains in the breast tissue. It can be assumed that with wavelet decomposition, MCCs are often among detail coefficients in mammograms [20]. This assumption is the basis for the proposed algorithm to improve the image contrast.

Several families of wavelets can be selected for the processing of mammography images. For these images, the orthogonality is the main criterion for selecting a family. Orthogonal properties allow the input image to be decomposed into independent coefficients. The Daubechies (dbN), Symlet (symN), and

Coiflet (coifN) wavelets are a family of orthogonal wavelets, which are suitable for mammograms. Based on the fact that wavelet coefficients represent the degree of similarity between the image and the mother wavelet, the following equations are used to assess the similarity between coefficients:

$$E_h = 100 \frac{\sum H^2}{\sum C^2}, E_v = 100 \frac{\sum V^2}{\sum C^2}, E_d = 100 \frac{\sum D^2}{\sum C^2} \quad (3)$$

In this study, five-level discrete wavelet decomposition was employed using Daubechies wavelet of order 8, since it accumulates more energy corresponding to the details of wavelet transform [21]; moreover, it is characterized by symmetry and finite length to enhance mammograms. Considering these features, this decomposition can attain a high correlation with the clustered MCCs, and therefore, it can enhance the visibility of MCCs. This produced an approximate coefficient and five sets of horizontal, vertical, and diagonal detail coefficients. After decomposition, the algorithm performed inverse wavelet transforms using these five sets of detail coefficients, and the approximate coefficients were set to zero.

**3. Results**

The proposed method in this study was applied for 120 digitized mammograms. Two examples of applying the proposed algorithm for contrast enhancement of images, containing MCCs, are presented in Figure 4.




Figure 4. Two examples of the proposed algorithm for two different mammograms, a) original ROI of the mammogram, (b) enhanced ROI

As shown in Figure 4, the proposed algorithm could improve image contrast, and thus, the MCCs were visible.

To evaluate the performance of the proposed algorithm, the contrast improvement index (CII) was used [22], which is defined as follows:

$$CII = \frac{C_{\text{processed}}}{C_{\text{original}}} \quad (4)$$

Where  $C_{\text{processed}}$  and  $C_{\text{original}}$  represent the contrast values of the processed and original images, respectively.

The contrast  $C$  of a region was defined by the following equation:

$$c = \frac{f - b}{f + b} \quad (5)$$

Where  $f$  is the mean gray-level value of the foreground, and  $b$  is the mean gray-level value of the background. The higher value of CII shows the best performance of the enhancement method. In Table 1, the contrasts of the original and enhanced images are indicated.

Table 1. The CII values of four different enhanced mammograms

	Contrast	Original	Wavelet transform	CLAHE	The proposed algorithm
Image1	C	0.1331	0.2054	0.2106	0.3596
	CII	-	1.54	1.58	2.7
Image2	C	0.1385	0.2367	0.2660	0.4533
	CII	-	1.70	1.92	3.27
Image3	C	0.1193	0.1850	0.2063	0.4279
	CII	-	1.55	1.73	3.58
Image4	C	0.1151	0.2738	0.3021	0.4216
	CII	-	2.37	2.62	3.66



To assess the quality of an image after enhancement, profile intensity surface area distribution curve was used. The intensity distribution curve was applied for the measured intensity distribution of MCCs as a function of size without any need for separating MCCs. This curve estimates the intensity surface area distribution of MCCs as a function of size and compares image objects

to stones, whose sizes can be determined by sifting them through screens of increasing size and collecting what remains after each pass. Image objects are sifted by opening the image with a structuring element of increasing size and counting the remaining intensity surface area (summation of pixel values in the image) after each opening [23]. The intensity curve of a mammogram is shown in Figure 5.

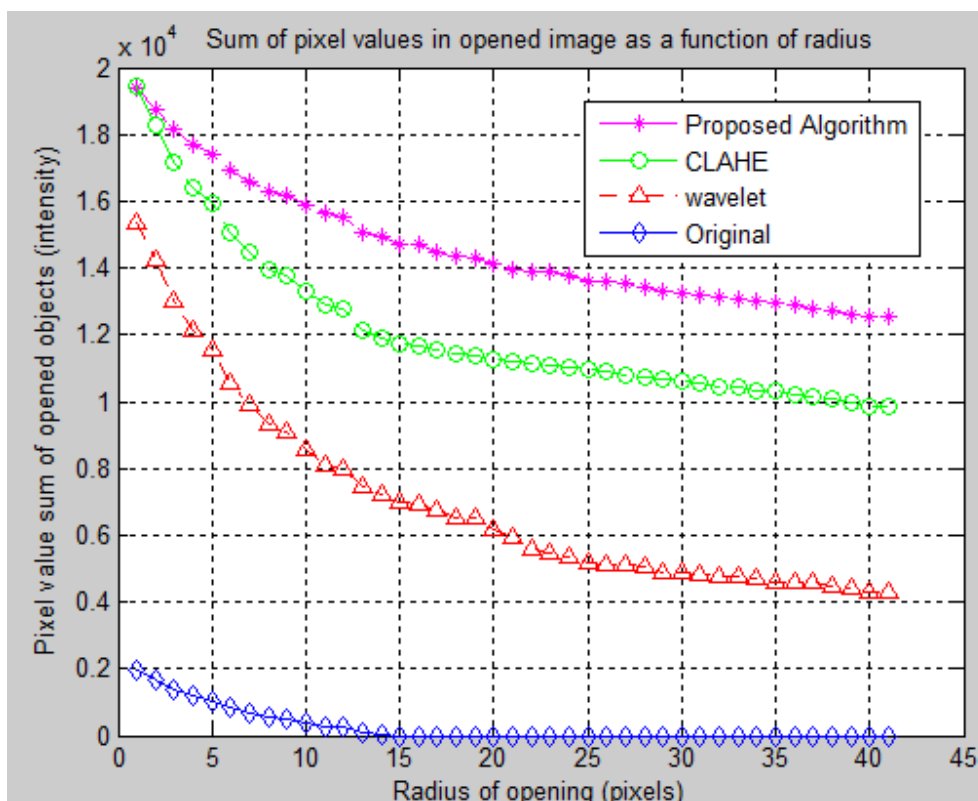


Figure 5. Intensity surface area distribution curve

As shown in Figure 5, the proposed algorithm achieved the highest intensity compared to the CLAHE and wavelet transform. This asserts that the proposed method in this research can effectively improve the image contrast.

#### 4. Discussion

The presences of MCCs are one of the earliest and most common signs of breast cancer. Detection of these signs in mammograms is more important than any other symptoms. Factors such as the large size and the low contrast of mammograms, as well as the small size, various patterns, and limited number of MCCs, make the detection of MCCs difficult

for the physicians. Considering the difficulties and the importance of detecting MCCs in breast cancer diagnosis, the need to use automatic methods is strongly felt in order to prevent the development of cancer cells.

In this study, a new method for improving mammography image contrast was presented in order to detect MCCs earlier and more accurately. The proposed method included four stages. Firstly, the images were scaled since the real size of mammogram images was too large. Secondly, the breast tissue was segmented from the background of the image. Thirdly, noise was removed using a sensitive filter in correspondence with the shape and size of MCCs (an adaptive median filter was



used for this purpose). Finally, the combined method of CLAHE and wavelet transform was used for contrast enhancement.

We selected the algorithms based on previous studies and tried to eliminate the associated disadvantages to identify features such as MCCs[11-13]. To evaluate the performance of the proposed algorithm, CII was used. The mean CII for the proposed algorithm in this study was 3.34 and for the wavelet and CLAHE was 1.81 and 1.98, respectively. This indicates that the suggested algorithm achieved the highest CII among others.

Two radiologists also evaluated the images, obtained by the proposed method. The results showed that this method could improve the accuracy and speed of MCCs detection. To implement the presented method, MATLAB software version 7.4 was used, which is applicable for conventional systems.

## 5. Conclusion

According to the results, the most useful characteristic of this system was the automatic contrast enhancement; however, although this method manually improved the image contrast, it was time-consuming.

In addition, it was believed that the proposed method in this paper has a more significant

effect on contrast enhancement of mammograms, compared to manual methods. The proposed method showed a more significant effect on dense breast tissue; however, the original images in some fatty breast tissue were preferred.

In general, the proposed algorithm could improve the physicians' diagnosis based on mammograms, decrease the number of biopsies, and reduce the frequency of clinical misdiagnosis.

Although the study results were satisfactory, the effective use of this model in medical centers needs further studies on more images. In future works, these results could be used in subsequent stages of CAD system such as segmentation and classification of benign and malignant patterns.

## Acknowledgment

The authors would like to thank all the participants who cooperated with us in this study. We also express our deepest gratitude to Dr. Mohammad Esmail Akbari, the chief of Iranian Cancer Research Center, for his sincere contributions and Mr. Hossein Khazaei, the reviewer of the article, for his valuable comments.

## References

1. Zare N, Haem E, Lankarani KB, Heydari ST, Barooti E. Breast cancer risk factors in a defined population: weighted logistic regression approach for rare events. *J Breast Cancer*. 2013 Jun;16(2):214-9.
2. Tang J, Rangayyan RM, Xu J, El Naqa I, Yang Y. Computer-aided detection and diagnosis of breast cancer with mammography: recent advances. *IEEE Trans Inf Technol Biomed*. 2009 Mar;13(2):236-51.
3. Cheng H-D, Cai X, Chen X, Hu L, Lou X. Computer-aided detection and classification of microcalcifications in mammograms: a survey. *Pattern Recognition*. 2003;36(12):2967-91.
4. Dean JC, Ilvento CC. Improved cancer detection using computer-aided detection with diagnostic and screening mammography: prospective study of 104 cancers. *AJR Am J Roentgenol*. 2006 Jul;187(1):20-8.
5. Thangavel K, Karnan M, Sivakumar R, Mohideen AK. Automatic detection of microcalcification in mammograms-a review. *International Journal on Graphics Vision and Image Processing*. 2005;5(5):31-61.
6. Nakayama R, Uchiyama Y, Yamamoto K, Watanabe R, Namba K. Computer-aided diagnosis scheme using a filter bank for detection of microcalcification clusters in mammograms. *IEEE Trans Biomed Eng*. 2006 Feb;53(2):273-83.
7. Bocchi L, Coppini G, Nori J, Valli G. Detection of single and clustered microcalcifications in mammograms using fractals models and neural networks. *Med Eng Phys*. 2004 May;26(4):303-12.
8. Ramírez-Cobo P, Vidakovic B. A 2D wavelet-based multiscale approach with applications to the analysis of digital mammograms. *Computational Statistics & Data Analysis*. 2013;58:71-81.
9. Mohan S, Ravishankar M. Modified contrast limited adaptive histogram equalization based on local contrast enhancement for mammogram images. *Mobile Communication and Power Engineering: Springer*; 2013. p. 397-403.

10. Papadopoulos A, Fotiadis DI, Costaridou L. Improvement of microcalcification cluster detection in mammography utilizing image enhancement techniques. *Comput Biol Med.* 2008 Oct;38(10):1045-55.
11. Zhang X, Homma N, Goto S, Kawasumi Y, Ishibashi T, Abe M, et al. A Hybrid Image Filtering Method for Computer-Aided Detection of Microcalcification Clusters in Mammograms. *Journal of Medical Engineering.* 2013;2013.
12. Moradmand H, Setayeshi S, Karimian AR, Sirous M, Akbari ME. Comparing the Performance of Image Enhancement Methods to Detect Microcalcification Clusters in Digital Mammography. *Iranian Journal of Cancer Prevention.* 2012;5(2):61-8.
13. Moradmand H, Setayeshi S, Khazaei H. Comparing Methods for segmentation of Microcalcification Clusters in Digitized Mammograms. *International Journal of Computer Science Issues.* 2011; 8: 104-8.
14. González RC, Woods RE. *Digital image processing*: Prentice Hall; 2002.
15. Hashimoto B. *Practical Digital Mammography*: Thieme;2011.
16. Yu S, Guan L. A CAD system for the automatic detection of clustered microcalcifications in digitized mammogram films. *IEEE Trans Med Imaging.* 2000 Feb;19(2):115-26.
17. Langarizadeh M, Mahmud R, Ramli AR, Napis S, Beikzadeh MR, Rahman WE. Improvement of digital mammogram images using histogram equalization, histogram stretching and median filter. *J Med Eng Technol.* 2011 Feb;35(2):103-8.
18. Yuan S-Q, Tan Y-H. Impulse noise removal by a global-local noise detector and adaptive median filter. *Signal Processing.* 2006;86(8):2123-8.
19. Zeng M, Li Y, Meng Q, Yang T, Liu J. Improving histogram-based image contrast enhancement using gray-level information histogram with application to X-ray images. *Optik-International Journal for Light and Electron Optics.* 2012;123(6):511-20.
20. Mencattini A, Salmeri M, Lojaco R, Frigerio M, Caselli F. Mammographic images enhancement and denoising for breast cancer detection using dyadic wavelet processing. *Instrumentation and Measurement, IEEE Transactions on.* 2008;57(7):1422-30.
21. Matsuyama E, Tsai DY, Lee Y, Tsurumaki M, Takahashi N, Watanabe H, et al. A modified undecimated discrete wavelet transform based approach to mammographic image denoising. *J Digit Imaging.* 2013 Aug;26(4):748-58.
22. Morton MJ, Whaley DH, Brandt KR, Amrami KK. Screening mammograms: interpretation with computer-aided detection--prospective evaluation. *Radiology.* 2006 May;239(2):375-83.
23. Lira C, Pina P. Granulometry on classified images of sand grains. *Journal of Coastal Research, ICS 2011 Proceedings, SI64.* 2011..