

Study of the Radio-Protective Effects of Henna Mixed With Vinegar on the Skin of Irradiated Rats

Mojgan Hasanzade¹, Mohammad Taghi Bahreyni Toossi², Masoumeh Gharib³, Shirin Taraz Jamshidi⁴, Hamid Gholamhosseinian², Shokouhazaman Soleymanifard^{*1,2}

1. Department of Medical Physics, Faculty of Medicine, Mashhad University of Medical Sciences, Mashhad, Iran.
2. Medical Physics Research Center, Mashhad University of Medical Sciences, Mashhad, Iran
3. Department of Pathology, Mashhad University of Medical Sciences, Mashhad, Iran.
4. Kidney Transplantation Complications Research Center, Mashhad University of Medical Sciences, Mashhad, I.R. Iran.

ARTICLE INFO

Article type:
Original Paper

Article history:
Received: May 30, 2022
Accepted: Oct 08, 2022

Keywords:
Radiation Protection
Henna
Skin
Grape Vinegar
Radiotherapy

ABSTRACT

Introduction: Skin damage is one of the most common challenges of radiation therapy. In the present study an attempt was made to evaluate the radio-protective effects of henna mixed with vinegar on the skin.

Material and Methods: The rats were divided into Control (no treatment), R (receiving radiation alone), V (receiving vinegar alone), H (receiving henna mixed with vinegar), R + H (receiving henna mixed with vinegar and then radiation), and R + V (receiving vinegar and then radiation) groups. All rats were euthanized and their skins' pathological damage and the level of super oxide dismutase (SOD) and Mallon dialdehyde (MDA) were evaluated. The rats were irradiated with 15 Gy (6MV) X-rays.

Results: Increase MDA and decrease SOD were seen in R group. However, these changes were ameliorated in R + H group, although the difference was not significant. Vinegar significantly decreased MDA induced by radiation, but could not increase the SOD level. The rate of skin pathological damage in R group were higher than in Control. However, the level of these lesions was lower in R + H and R + V groups compared to R group. The rate of dermatitis and sweat gland atrophy in R + H and R + V groups were less than R group and similar to the level in the control group.

Conclusion: Henna and vinegar could reduce the skin injuries induced by radiation. Regarding pathological injuries, the effects of vinegar alone was more than henna, but regarding antioxidant activity, the protective effect of henna mixed with vinegar was better than vinegar alone.

► Please cite this article as:

Hasanzade M, Bahreyni Toossi MT, Gharib M, Taraz Jamshidi Sh, Gholamhosseinian H, Soleymanifard Sh. Study of the Radio-Protective Effects of Henna Mixed With Vinegar on the Skin of Irradiated Rats. Iran J Med Phys 2024; 21: 249-257. 10.22038/ijmp.2022.65850.2128.

Introduction

Radiation therapy is an important method used in cancer treatment, in which tumors are exposed to ionizing radiation [1]. Radiation reacts with biomolecules directly, or interacts with water molecules and produces free radicals which in turn damages bimolecular structures of the cancerous cells[2]. Owing to impairments occur in these cells, they undergo the processes that end to cell death. However, radiation also damages normal cells and causes side effects on healthy tissues[3].

Skin is exposed to radiation and is likely to be injured, especially at high doses. The skin consists of epidermis, dermis and subcutaneous glands, collagen fibers, hair follicles, and sebaceous glands[4]. Radiation-induced skin reactions include severe erythema and wet wounds. These complications reduce the quality of patients' lives and therefore, the radiation dose must be limited, which in turn disrupts efficacy of tumor treatment. Skin injuries may also interrupt the course of radiotherapy. Therefore, it is

necessary to protect the skin from radiation and prevent the above mentioned conditions [5, 6].

Radioprotectors are considered as a solution [7]. Radioprotectors use a series of mechanisms to safeguard normal tissues. They may scavenge the free radicals produced by radiation, decrease the inflammation, or activate the mechanisms of DNA repair in irradiated cells[8]. Due to inherent toxicity of radioprotectors, they cannot be used at any concentration [9]. Fortunately, natural radioprotectors derived from plants have less toxicity and have attracted attention from scientists. For example, it has been observed that derivatives of some plants stimulate the proliferation of hematopoietic cells injured by radiation and consequently protect hemopoietic system from cell depletion[10]. Henna (*Lawsonia inermis* L.; syn. *Lawsonia alba* L.) is an herbal plant with high antioxidant and immunomodulatory properties [11-13]. It has wound healing feature [14], and reduces the activity of microorganisms and prevents the infection

*Corresponding Author: Tel: +98-5138002333; Email: soleymanifardsh@mums.ac.ir

caused by skin burns [15, 16]. In addition, it exhibits anticancer properties [17, 18]. For instance, DK Singh et al., observed that when a certain amount of henna powder was poured into the drinking water of mice, they became resistant to UV-B rays and were less likely to suffer from skin cancer [17]. The authors emphasized on anti-melanogenesis functions of henna [19]. In another study carried out by Yaralizadeh et al, the researchers proved that a vaginal cream made from henna was able to treat *Candida albicans* infections in female mice [20]. It has also been demonstrated that henna gel heals wounds and prevent inflammation in mice [21].

As henna has antioxidant activity, scavenges free radicals, and has anti-inflammatory properties we have anticipated that it may protect the skin against radiation-induced damages when implemented before irradiation. Therefore, this study was planned to investigate whether applying henna on the skin can reduce the radiation damage to the skin and act as a radioprotector. As vinegar has antioxidant properties and is a better carrier for henna compared to water, henna was mixed with vinegar.

Materials and Methods

The mice and materials

Thirty-eight male Wistar rats, weighing 150 to 210 gr, were housed at 22 ± 2 °C with periodical illumination from 7:00 a.m. to 7:00 p.m. food pellets and water were also available. Animal handling and all related procedures were carried out according to Mashhad University of Medical Sciences, Ethical Committee Acts (IR.MUMS.MEDICAL.REC.13980558).

Henna with E1157-FUMH herbarium code and the wine vinegar were purchased from Dr. Tairani Pharmacy.

The groups of rats

The rats were divided into three groups. Some rats were treated with henna mixed in vinegar, others were treated with just vinegar, and the third group did not receive any of the above treatments.

Half of each group was irradiated with 15 Gy X-rays (Elekta, Stockholm, Sweden). Therefore, we had six groups including: the rats that were treated with 1-

nothing (Control group), 2- henna mixed with vinegar (H group), 3- only vinegar (V group), 4- only radiation (R group), 5- henna mixed with vinegar and radiation (H+R group), 6- vinegar and radiation (V+R group). Each group consisted of 5 rats.

Preparation of a mixture of henna and wine vinegar

To treat the rats with the mixture of henna and vinegar, 20 gr of henna extract was mixed in 55ml of wine vinegar (Concentration 0.36 gr/ml). Then the concentration of the mixture declined to 0.4 gr/ml. The back of all the rats was shaved. Afterwards, H and H+R groups received the mixture on their back. To this aim, the mixture was placed on the back of the rats for 2 hours and was then washed with water. V and V+R groups were treated similarly with vinegar.

Irradiation

Two days later, the rats in R, H+R, and V+R groups were irradiated with 15 Gy X-rays. The skin of the rats was covered with 1.5 cm bolus, and by applying a 5*5 cm² radiation field, a small part of the rat's bodies, covered by a part of 5*5 cm² field, was irradiated with 6 MV X-rays (Elektra, Stockholm, Sweden) (Figure 1). The distance between the X-ray source and the skin was 98.5 cm; and the dose rate was 200 cGy/min. The rats in other groups were sham irradiated.

Five to seven days after irradiation, the rats were euthanized with carbon monoxide and their skin samples were prepared.

Histological evaluation of the skin samples

Tissue pieces of the skin were obtained from the posterior surface of the rat's body and were fixed in 10% formalin. Then they were embedded in paraffin and dissected at parts of 4-μm-thick slices sections and stained with hematoxylin and eosin (H+E) in order to be processed for routine pathology examinations using light microscopic evaluation. The radiation effects were evaluated using different parameters.

Based on a previous study [22], the following criteria was employed to examine the atrophy, fibrosis, and inflammation of the skin samples.

Grade 0 = normal, Grade 1 = mild, Grade 2 = moderate, Grade 4 = severe

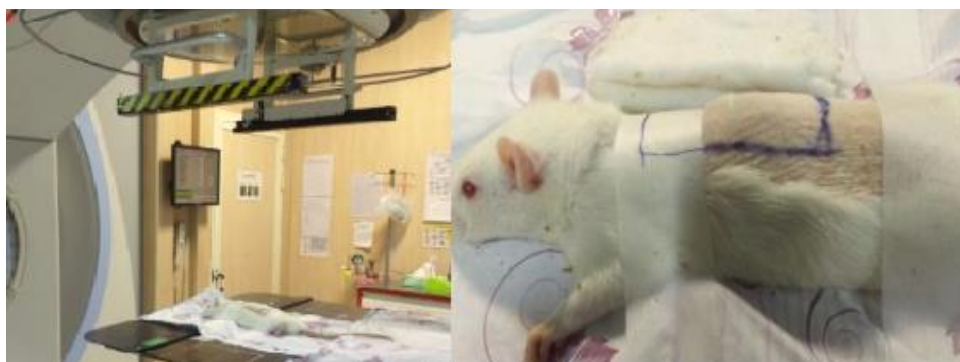

Figure 1. Local radiation on the shaved back of the rat in the 5 * 5 field.

Antioxidant Enzymes assay

According to the method used by Nishikimi et al. [23], the tissue samples were homogenized and their antioxidant activity (the level of superoxide dismutase (SOD) and Malon dialdehyde (MDA) were evaluated.

The activity of SOD in skin samples was evaluated by a calorimetric method, as described previously [24]. The method is based on the inhibition of production of superoxide anion due to auto-oxidation of pyrogallol and MTT oxidation; SOD activity was expressed as unit/mg protein. To measure the level of MDA, a sample of 0.5 mL of the homogenized tissues (skin) was mixed with 0.5 mL of deionized water, and 0.5 mL of TCA reagent (TCA 15% and TBA 0.37%, HCl 0.25 N). The reaction mixture was incubated for 60 min at 95 °C and after cooling, 25 µl of HCl and 1.5 mL of n-butanol were added to the mixture. After centrifuging at 1000 rpm for 10 min, the fluorescence of the supernatant was measured using fluorescent plate reader (PerkinElmer VICTOR X5, USA) at an excitation of 485 nm and an emission of 535 nm. Tetraethoxypropane was used to prepare a standard curve at concentration ranges between 0.01- 0.2 mmol/L.

Statistical analysis

To analyze the results of this study, Graph pad Prism software version 6 was used and since the biochemical data were distributed normally, one-way ANOVA test was used to compare the groups.

Results

Biochemical results

Figure 2 shows the level of MDA measured in different groups. As it can be seen in the figure, MDA level was the highest in R group, in which the radiation increases MDA level ($p>0.05$). The level of MDA in R+H group was lower than in R group, but the difference was not statistically significant ($p>0.05$). Moreover, the difference between Control and R+H groups was not significant ($p>0.05$). Surprisingly, vinegar decreased MDA level that was increased by radiation, the MDA level in R+V group was significantly lower than in R group ($p<0.05$).

The results of SOD level are shown in Figure 3. The SOD level in R group was the lowest of all and was statistically different from Control group ($p<0.05$). The use of henna resulted in an increase in the level of SOD in R+H group, but the increase was not statistically significant ($p>0.05$). In addition, the difference between R+H and Control groups was also not significant ($p>0.05$). The effect of vinegar on SOD was unexpected, because the level of SOD in R+V group was even non-significantly lower than in the R group ($P>0.05$).

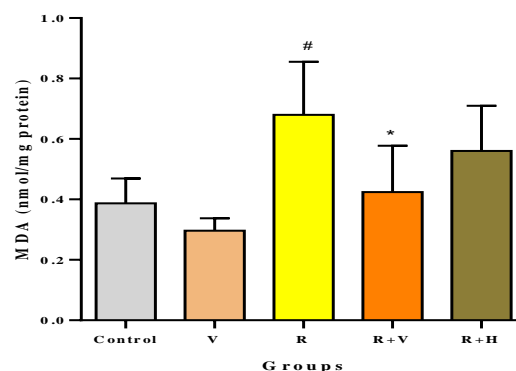


Figure 2. Measured MDA level in different groups. Control: no treatment, V: group receiving grape vinegar without radiation, R: group receiving radiation, R + V: group receiving radiation + grape vinegar, R + H: group receiving radiation + henna mixed in vinegar. The * sign indicates $p<0.05$ relative to the R group, the # sign indicates $p<0.05$ relative to the Control group

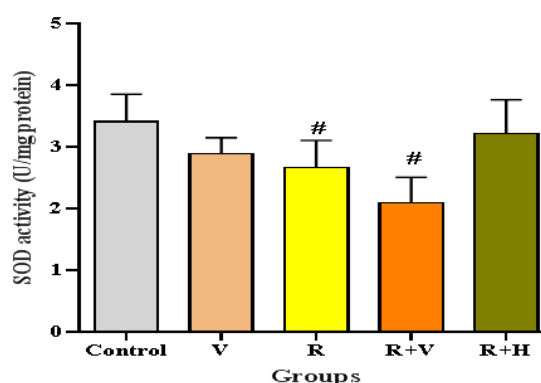


Figure 3. Measured SOD level in different groups. Control: group without treatment, V: group receiving grape vinegar without radiation, R: group receiving radiation, R + V: group receiving radiation + grape vinegar, R + H: group receiving radiation + henna mixed in vinegar. The * sign indicates $p<0.05$ relative to the R group, the # sign indicates $p<0.05$ relative to the Control group.

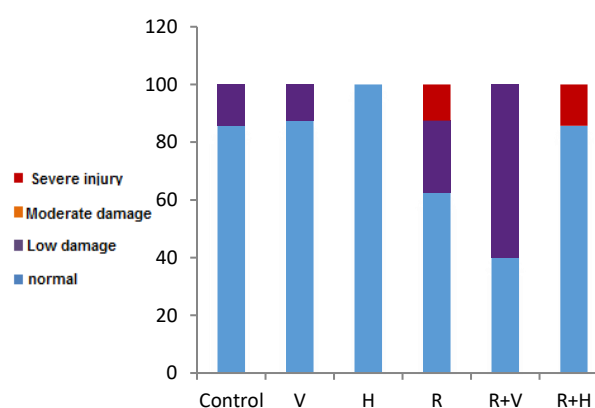


Figure 4. The percentage of skin fibrosis with different degrees of damage in the groups.

Table 1. Number and percentage of skin fibrosis in different groups

Variable	Division		Control	V	H	R	R+V	R+H
Cutaneous fibrosis	normal	Number	6	7	5	5	2	6
		Percentage	85.7	87.5	100	62.5	40.0	85.7
	Low damage	Number	1	1	0	2	3	0
		Percentage	14.3	12.5	0	25.0	60.0	0
	Moderate damage	Number	0	0	0	0	0	0
		Percentage	0	0	0	0	0	0
	Severe injury	Number	0	0	0	1	0	1
		Percentage	0	0	0	12.5	0	14.3

Pathological results

The results of pathological examination of the skin of rats are shown in Figures 4- 9. The colored columns in the figures show the percentage of the rats with different degrees of damage.

Figure 4 and Table 1 show the level of fibrosis among groups. Since radiation induced fibrosis, the percentage of the rats with severe and low injuries in R group was more than in control group. Henna mixed with vinegar could decrease the level of injuries, therefore, there are no low grade injuries in R+H group. But, the level of severe injuries is similar to R group. Vinegar was more effective than the mixture and completely eliminated the severe injuries induced by radiation.

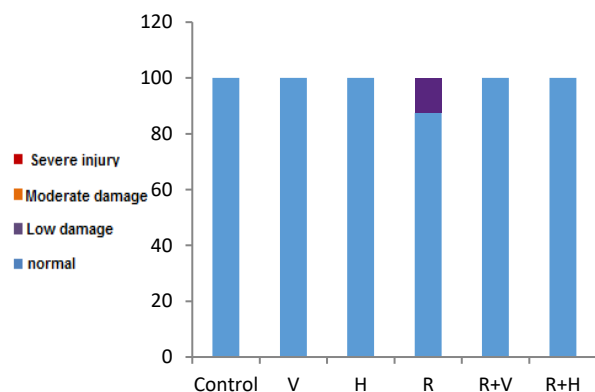


Figure 5. The percentage of skin inflammation with different degrees of damage in the groups

Table 2. Number and percentage of skin inflammation in different groups

Variable	Division		Control	V	H	R	R+V	R+H
skin inflammation	normal	Number	7	7	5	7	5	7
		Percentage	100	100	100	87.5	100	100.0
	Low damage	Number	0	0	0	1	0	0
		Percentage	0	0	0	12.5	0	0
	Moderate damage	Number	0	0	0	0	0	0
		Percentage	0	0	0	0	0	0
	Severe injury	Number	0	0	0	0	0	0
		Percentage	0	0	0	0	0	0

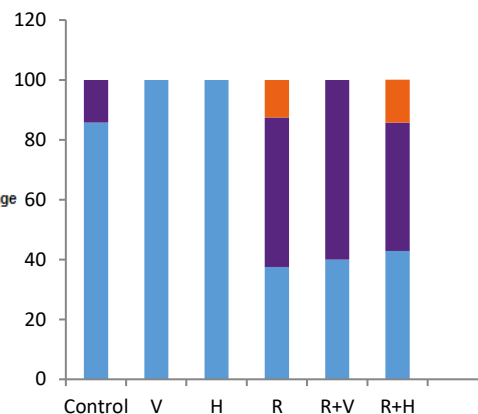


Figure 6 The percentages of epidermal atrophy in different degrees in the groups

Figure 5 and Table 2 show the percentage of the mice with different levels of inflammation in the groups. As it can be seen, radiation resulted in just low inflammation damage in 12.5% of the mice; however, both vinegar and henna mixed with vinegar could prevent such injuries in mice; therefore, all mice in R+V and R+H groups were similar to normal group.

As seen in Figure 6 and Table 3, radiation resulted in moderate and low-level epidermal atrophy, in which henna mixed with vinegar could not prevent it. No difference in the percentage of the mice with different degrees of atrophy in R and R+H groups was observed. On the other hand, vinegar had a preventive effect, since it changed moderate injuries in R+V group into low injuries.

Table 3. Number and percentage of epidermal atrophy in different groups

Variable	Division		Control	V	H	R	R+V	R+H
epidermal atrophy	normal	Number	6	8	5	3	2	3
		Percentage	85.7	100	100	37.5	40.0	42.9
	Low damage	Number	1	0	0	4	3	3
		Percentage	14.3	0	0	50.0	60.0	42.9
	Moderate damage	Number	0	0	0	1	0	1
		Percentage	0	0	0	12.5	0	14.3
	Severe injury	Number	0	0	0	0	0	0
		Percentage	0	0	0	0	0	0

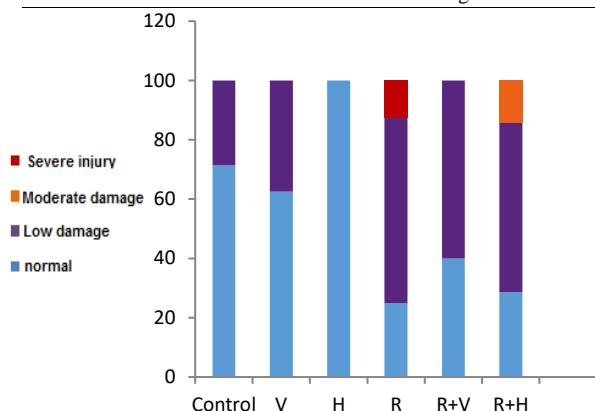


Figure 7. The percentages of the hair follicle atrophy in different degrees in the groups

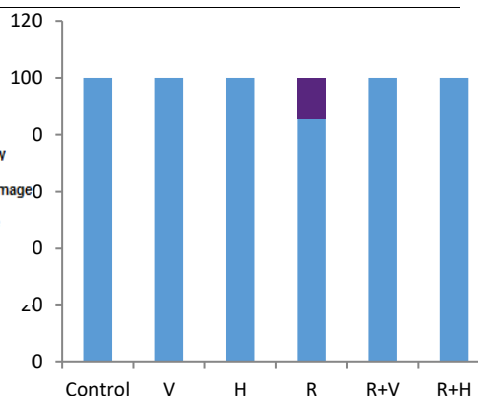


Figure 9. The percentages of the sweat gland atrophy in the groups

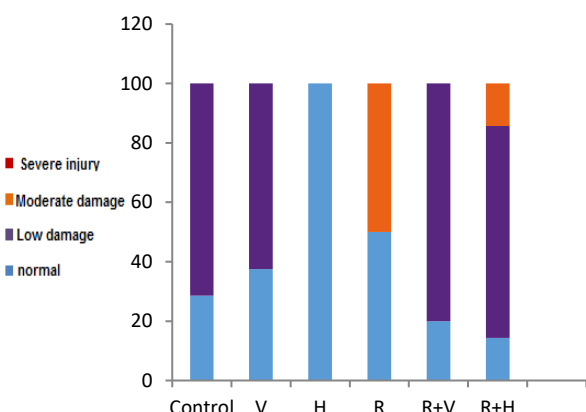


Figure 8. The percentages of sebaceous gland atrophy in different degrees in the groups

Damage to hair follicles is shown in Figure 7 and Table 4. Radiation caused severe and low follicle atrophy, but henna mitigated the severe damage to moderate damage; although, it did not change the percentage of the mice with low level follicle atrophy. Since, vinegar has a more protective effect compared to henna, neither severe nor moderate injuries are observed in R+V group, but poor follicular atrophy has been detected.

Figure 8 and Table 5 illustrate the level of sebaceous gland atrophy in different groups. Radiation resulted in moderate injuries in 50% of the mice. However, in R + V group, no moderate injuries were observed, but in R + H group, only the amount of moderate-grade injuries has decreased compared to R group (from 50% in R group to 14.3 % in R+H group). Figure 9 and Table 6 illustrate the level of sweat gland atrophy. Radiation induced low grade injuries in sweat glands (in 14.3% of the mice); however, both henna and vinegar could prevent radiation-induced atrophy in these glands.

Table 4. Number and percentage of hair follicle atrophy in different groups

Variable	Division		Control	V	H	R	R+V	R+H
Hair follicle atrophy	normal	Number	5	5	5	2	2	2
		Percentage	71.4	62.5	100	25.0	40.0	28.6
	Low damage	Number	2	3	0	5	3	4
		Percentage	28.6	37.5	0	62.5	60.0	57.1
	Moderate damage	Number	0	0	0	0	0	1
		Percentage	0	0	0	0	0	14.3
	Severe injury	Number	0	0	0	1	0	0
		Percentage	0	0	0	12.5	0	0

Table 5. Number and percentage of sebaceous gland atrophy in different groups

Variable	Division		Control	V	H	R	R+V	R+H
Sebaceous gland atrophy	normal	Number	2	3	5	4	1	1
		Percentage	28.6	37.5	100	50.0	20.0	14.3
	Low damage	Number	5	5	0	0	4	5
		Percentage	71.4	62.5	0	0	80.0	71.4
	Moderate damage	Number	0	0	0	4	0	1
		Percentage	0	0	0	50.0	0	14.3
	Severe injury	Number	0	0	0	0	0	0
		Percentage	0	0	0	0	0	0

Table 6. Number and percentage of sweat gland atrophy in different groups

Variable	Division		Control	V	H	R	R+V	R+H
Sweat gland atrophy	normal	Number	7	8	5	6	5	7
		Percentage	100	100	100	85.7	100	100
	Low damage	Number	0	0	0	1	0	0
		Percentage	0	0	0	14.3	0	0
	Moderate damage	Number	0	0	0	0	0	0
		Percentage	0	0	0	0	0	0
	Severe injury	Number	0	0	0	0	0	0
		Percentage	0	0	0	0	0	0

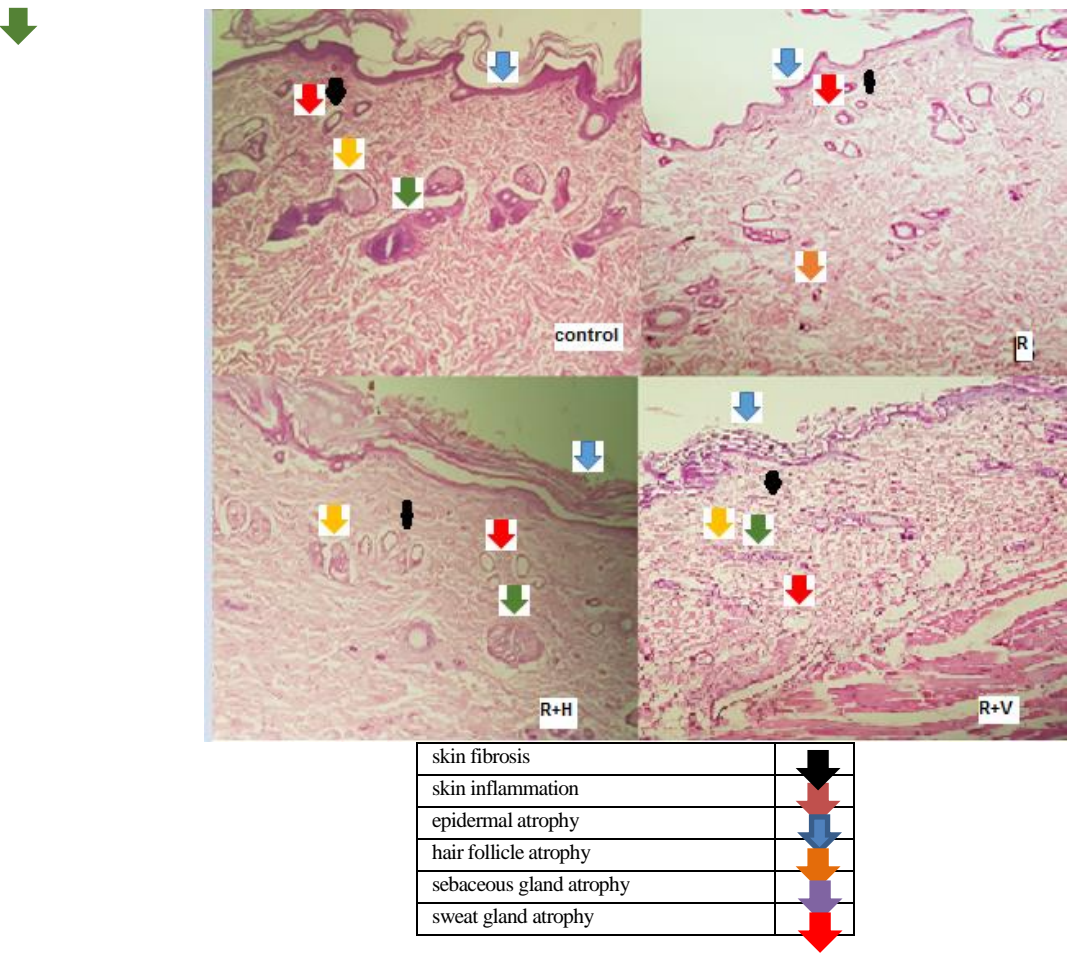


Figure 10. Microscopic view of the skin tissue (Hematoxylin-Eosin staining) to evaluate skin lesion

Microscopic images of skin tissue

In Figure 10, the skin fibrosis is indicated by a black arrow mark. For R group, the sweat glands are very close to one another, which is a sign of skin fibrosis, and this situation is slightly better in R + H sample compared to R and is almost similar to the control and R + V. Area of skin inflammation is indicated by an orange arrow mark. The orangheads shown in the figure indicate inflammation that is only seen in group R and not in the other groups. Area of Epidermal atrophy is indicated by a blue arrow mark. The rate of atrophy in epidermis in group R is much higher than in control, and as the figure shows, the epidermis is very thin. But, its intensity in R + V group is lower than in R. R + H group has better conditions than R group.

Area of Hair follicle atrophy is indicated by a green arrow mark. The sebaceous glands are attached to the hair follicles and based on the shape, we can observe that in R sample, hair follicle damage is so severe that no hair follicle is detected. However, the condition of R + H group is better than R, and R + V is close to control. Area of Sebaceous gland atrophy is indicated by a yellow arrow mark. The sebaceous glands are attached to the hair follicles and based on the shape, we could see that in the R sample the atrophy of the hair follicle is so severe that the hair follicles disappeared. But, less injuries are observed in R + H compared to R, and R + V is close to control. Area of sweat gland atrophy is indicated by a red arrow mark. These glands shrank and showed damage in the radiation group, but the other groups showed no damage/injuries and had a similar condition to control group.

Discussion

When tumors are irradiated, complications such as pain, wounds and infection are usually visible in the skin of patients. Sometimes, late side effects like Ataxia telangiectasia may occur as a result of a high dose irradiation. These complications may not only reduce the quality of life, but they also cause an interruption in the treatment [25, 26]. Hence, using radioprotectors, in order to reduce the radiation-induced skin injuries, is a necessity. For this purpose, different chemical substances have been proposed [10]. However, as most of them are toxic, natural compounds have attracted special attention [27]. One of the most important features of radioprotectors is their antioxidant properties, which result in the removal of free radicals produced by ionizing radiation. This property is seen in a large number of natural compounds [28, 29]. Henna is one of them with efficient antioxidant properties [30, 31]. Therefore, the present study was performed to investigate if henna can protect the skin against radiation.

As henna should be mixed with a liquid, we mixed it with vinegar. The reason was the fact that henna in combination with vinegar releases more antioxidant into the skin compared to a combination of henna and water. Furthermore, our preliminary experiment revealed that Henna mixed with vinegar penetrates into the skin and colors the skin more effectively than when it is mixed

with water; therefore, in the present study it was mixed with vinegar. On the other hand, since vinegar had its own impact, we studied the effects of vinegar on the skin of mice separately to distinguish its effects from henna. Hence, we have evaluated the effects of henna on the skin of rats in H and R+H groups, along with the effects of vinegar in V and R+V groups. Moreover, irradiation was performed with 15 Gy X-rays in one session, since our pilot study demonstrated that biochemical and pathological damages occurred with this dose of radiation after one week. Although 15 Gy irradiation in one session is much higher than the common dose/fraction used in clinics, it helped us prevent the suffering of the mice from multiple anesthesia for several sessions. Besides, the rats were euthanized and sampled 5 to 7 days after irradiation to allow the skin to show its damage on the microscopic slides. On the other hand, due to the high radiation dose that the animals received which caused gastrointestinal damage, they could not be alive for a longer period of time. Santin et al. also performed a study with the same interval [32].

One of the most important features that radioprotectors must possess is their inherent non-toxicity [10]. Fortunately, the results showed that henna mixed with vinegar and vinegar alone had no toxicity on the skin, since no adverse effects were observed in H and V groups. However, as predicted, radiation damaged the skin. The results showed that SOD level in the irradiation group was lower than the control group. The reason for this decrease is the increase of free radicals in the skin of irradiated rats, which causes the consumption of SOD. The results also indicated that the level of MDA in the skin of irradiated rats was higher than in the control group, indicating that lipid peroxidation was induced by oxidative stress.

Based on our prediction, SOD level in R + H group was higher than in R group, which indicated that the mixture of henna and vinegar increased SOD level, although this increase was not significant ($P > 0.05$). As similarly, the difference between SOD in R + H group and control group was not significant, it may be concluded that the mixture of henna and vinegar had a relative protection in reducing oxidative stress caused by radiation. The same was true for MDA. The mixture reduced the amount of MDA (prevented lipid peroxidation), but the difference between R and R + H was not significant. At the same time, there was no significant difference between Control and R+H groups in their amount of MDA, which again indicates the relative effectiveness of the mixture. In other words, the mixture could not create a significant difference between R+H and R groups, but it increased the value of SOD and decreased the amount of MDA up to the level observed in Control group ($P > 0.05$ for R+H and Control group). Therefore, it can be suggested that henna mixed with vinegar had a relative effectiveness which increased the level of SOD and decreased MDA level. To compare the effectiveness of the mixture with vinegar alone, it can be said that regarding MDA level,

vinegar had a greater effect than the mixture of henna and vinegar; however, considering the effect on elevating the amount of SOD, the mixture of henna and vinegar was more effective than vinegar alone. MDA reduction and SOD increase were observed in other skin radioprotectors. For instance, in a study carried out by Ihsan et al. Melatonin reduced MDA level and increased SOD level of the skin of rats. It also reduced other skin side effects induced by radiation [33]. XiaolingLu et al, also showed that Betaine in red beets protects the mice against radiation by reducing the amount of MDA and increasing SOD [34].

The results of pathology tests showed that 15 Gy radiation induces severe cutaneous fibrosis and hair follicle atrophy, moderate epidermal and sebaceous atrophy, and low-level inflammation and sweat gland atrophy. Using a mixture of henna and vinegar before irradiation caused a complete removal of low-level inflammation and sweat gland atrophy induced by radiation. The same effect was observed for vinegar alone. Hence, it is concluded that both henna mixed with vinegar and vinegar alone prevented low-level skin damages induced by radiation.

Henna mixed with vinegar also prevented low-level cutaneous fibrosis, but did not affect the amount of severe cutaneous fibrosis. However, vinegar alone could prevent and completely eliminate severe cutaneous fibrosis. Moderate level of hair follicle atrophy is reported in the mixture of henna and vinegar; however, vinegar alone had a more positive effect with less injuries. The higher protective effect of vinegar compared to henna mixed with vinegar could be observed again when sebaceous atrophy was measured. Henna mixed with vinegar decreased the percentage of the mice with moderate sebaceous atrophy, while vinegar completely eliminated moderate-level damage and turned them into low-level sebaceous atrophy.

Based on the above data, it can be concluded that both henna and vinegar showed radioprotection properties to maintain skin tissue, but as seen in most cases, the protective properties of vinegar alone, except in the case of SOD levels, was more than the mixture of henna and vinegar. Overlay, in severe (hair follicle atrophy) or moderate (fibrosis, epidermal atrophy and sebaceous gland atrophy) damages, vinegar has a greater protective effect compared to henna mixed with vinegar. But in case of low-grade damages (inflammation and atrophy of the sweat glands), the effect was the same for both.

According to the obtained data, we cannot compare vinegar and henna alone, because we did not consider a group receiving henna alone or mixed with water. The reason was the fact that the radio-protective properties of vinegar was not predicted and it was just used as a carrier for henna. It was thought that the antioxidant properties of henna are most effective when mixed with vinegar. However, the results showed that vinegar itself has antioxidant and radio-protective properties. In other words, to compare radioprotective effects of henna and vinegar, it is necessary to consider a group that receives

only henna. Therefore, for future studies, it is proposed to mix henna with water and compare its effect with vinegar.

Conclusion

According to the findings of this study, it can be concluded that a mixture of henna and vinegar can prevent the low-level skin injuries induced by radiation, but it could not completely prevent severe and moderate injuries. In fact, it could just relatively decrease the damage. To sum up, it can be concluded that the protective effect of vinegar alone was higher than the mixture of henna and vinegar, in which vinegar was more effective in eliminating or reducing severe and moderate damages to the skin. As the protective effects of vinegar alone were more than a mixture of henna and vinegar, it seems that henna decreases the radioprotective effect of vinegar. However, henna may have its own radioprotective effects, which can be investigated when henna is mixed in water. Therefore, future studies should investigate the radioprotective effects of henna separately from vinegar.

Acknowledgment

The authors would like to thank the Office of the Vice-President for Research Affairs of Mashhad University of Medical Sciences (MUMS) for funding this work. This article is based on the results extracted from an M.Sc. thesis (code no:) presented to the Medical Physics Department of MUMS. The authors state that they have no conflicts of interest to declare.

References

1. Barton MB, Frommer M, Shafiq J. Role of radiotherapy in cancer control in low-income and middle-income countries. *The lancet oncology*. 2006;7(7):584-95.
2. Wallace SS. Enzymatic processing of radiation-induced free radical damage in DNA. *Radiation research*. 1998;150(5s):S60-S79.
3. Barazzuol L, Coppes RP, van Luijk P. Prevention and treatment of radiotherapy-induced side effects. *Molecular Oncology*. 2020.
4. Lai-Cheong JE, McGrath JA. Structure and function of skin, hair and nails. *Medicine*. 2017;45(6):347-51.
5. Xiao Y, Mo W, Jia H. Ionizing radiation induces cutaneous lipid remodeling and skin adipocytes confer protection against radiation-induced skin injury. *Journal of dermatological science*. 2020;97(2):152-60.
6. Wan Y, Tu W, Tang Y. Prevention and Treatment for Radiation-Induced Skin Injury during Radiotherapy. *Radiation Medicine and Protection*. 2020.
7. Patyar RR, Patyar S. Role of drugs in the prevention and amelioration of radiation induced toxic effects. *European journal of pharmacology*. 2018;819:207-16.
8. Chandrasekharan DK, Khanna PK, Nair CKK. Cellular radioprotecting potential of glycyrrhizic acid, silver nanoparticle and their complex. *Mutation Research/Genetic Toxicology and Environmental Mutagenesis*. 2011;723(1):51-7.

9. Basaga H, Tekkaya C, Acikel F. Antioxidative and free radical scavenging properties of rosemary extract. *LWT-Food Science and Technology*. 1997;30(1):105-8.
10. Mun G-I, Kim S, Choi E. Pharmacology of natural radioprotectors. *Archives of Pharmacol Research*. 2018 2018/11/01;41(11):1033-50.
11. Mikhaeil BR, Badria FA, Maatooq GT. Antioxidant and immunomodulatory constituents of henna leaves. *Zeitschrift für Naturforschung C*. 2004;59(7-8):468-76.
12. Hosein HKM, Zinab D. Phenolic compounds and antioxidant activity of henna leaves extracts (*Lawsonia inermis*). *World Journal of Dairy & Food Sciences*. 2007;2(1):38-41.
13. Al-Damegh MA. Evaluation of the antioxidant activity effect of henna (*Lawsonia inermis* Linn.) leaves and or vitamin C in rats. *Life Sci J*. 2014;11:234-41.
14. Sakarkar DM, Sakarkar UM, Shrikhande VN, Vyas JV, Mandavgade S, Jaiswal SB, et al. Wound healing properties of Henna leaves.
15. Al-Rubiay KK, Jaber NN, Al-Mhaawe BH, Alrubaiy LK. Antimicrobial efficacy of henna extracts. *Oman medical journal*. 2008 Oct;23(4):253.
16. Hadisi Z, Nourmohammadi J, Nassiri SM. The antibacterial and anti-inflammatory investigation of *Lawsonia inermis*-gelatin-starch nano-fibrous dressing in burn wound. *International journal of biological macromolecules*. 2018;107:2008-19.
17. Singh DK, Luqman S. *Lawsonia inermis* (L.): a perspective on anticancer potential of mehndi/henna. *Biomedical Research and Therapy*. 2014;1(04):112-20.
18. J Kapadia G, Subba Rao G, Sridhar R, Ichiishi E, Takasaki M, Suzuki N, et al. Chemoprevention of skin cancer: effect of *Lawsonia inermis* L.(Henna) leaf powder and its pigment artifact, lawsone in the Epstein-Barr virus early antigen activation assay and in two-stage mouse skin carcinogenesis models. *Anti-Cancer Agents in Medicinal Chemistry (Formerly Current Medicinal Chemistry-Anti-Cancer Agents)*. 2013 Dec 1;13(10):1500-7.
19. Nakashima S, Oda Y, Nakamura S, Liu J, Onishi K, Kawabata M, et al. Inhibitors of melanogenesis in B16 melanoma 4A5 cells from flower buds of *Lawsonia inermis* (Henna). *Bioorganic & Medicinal Chemistry Letters*. 2015 Jul 1;25(13):2702-6.
20. Yarzadeh M, Abedi P, Namjoyan F, Fatahinia M, Chegini SN. A comparison of the effects of *Lawsonia inermis* (Iranian henna) and clotrimazole on *Candida albicans* in rats. *Journal de Mycologie Médicale*. 2018 Sep 1;28(3):419-23.
21. Jridi M, Sellimi S, Lassoued KB, et al. Wound healing activity of cuttlefish gelatin gels and films enriched by henna (*Lawsonia inermis*) extract. *Colloids and Surfaces A: Physicochemical and Engineering Aspects*. 2017;512:71-9.
22. Sibin Melo KC, Correia MH, Svidzinski TI, Hernandez L. Exocellular extract of *Fusarium oxysporum*, fungus free, is able to permeate and act selectively in skin. *Apmis*. 2018 May;126(5):418-27.
23. Beyer Jr WF, Fridovich I. Assaying for superoxide dismutase activity: some large consequences of minor changes in conditions. *Analytical biochemistry*. 1987;161(2):559-66.
24. Madesh M, Balasubramanian K. Microtiter plate assay for superoxide dismutase using MTT reduction by superoxide. *Indian journal of biochemistry & biophysics*. 1998;35(3):184-8.
25. Salvo N, Barnes E, Van Draanen J, Stacey E, Mitera G, Breen D, Giotis A, et al. Prophylaxis and management of acute radiation-induced skin reactions: a systematic review of the literature. *Current oncology*. 2010 Aug;17(4):94.
26. Connell PP, Hellman S. Advances in radiotherapy and implications for the next century: a historical perspective. *Cancer research*. 2009;69(2):383-92.
27. Yamini K, Gopal V. Natural radioprotective agents against ionizing radiation-an overview. *International Journal of PharmTech Research*. 2010;2(2):1421-6.
28. Weiss JF, Landauer MR. Radioprotection by Antioxidants a. *Annals of the New York Academy of Sciences*. 2000;899(1):44-60.
29. Samarth RM, Panwar M, Kumar M, Soni A, Kumar M, Kumar A. Evaluation of antioxidant and radical-scavenging activities of certain radioprotective plant extracts. *Food chemistry*. 2008 Jan 15;106(2):868-73.
30. Hsouna AB, Trigui M, Culioli G, Blache Y, Jaoua S. Antioxidant constituents from *Lawsonia inermis* leaves: Isolation, structure elucidation and antioxidative capacity. *Food Chemistry*. 2011 Mar 1;125(1):193-200.
31. Duan W, Xia T, Zhang B, Li S, Zhang C, Zhao C, et al. Changes of physicochemical, bioactive compounds and antioxidant capacity during the brewing process of Zhenjiang aromatic vinegar. *Molecules*. 2019 Oct 31;24(21):3935.
32. da Silva Santin M, Koehler J, Rocha DM, Dos Reis CA, Omar NF, Fidler Y, et al. Initial damage produced by a single 15-Gy x-ray irradiation to the rat calvaria skin. *European Radiology Experimental*. 2020 Dec;4:1-0.
33. Karslioglu I, Ertekin MV, Taysi S, et al. Radioprotective effects of melatonin on radiation-induced cataract. *Journal of radiation research*. 2005;46(2):277-82.
34. Lu X, Wang Y, Zhang Z. Radioprotective activity of betalains from red beets in mice exposed to gamma irradiation. *European journal of pharmacology*. 2009;615(1-3):223-7.